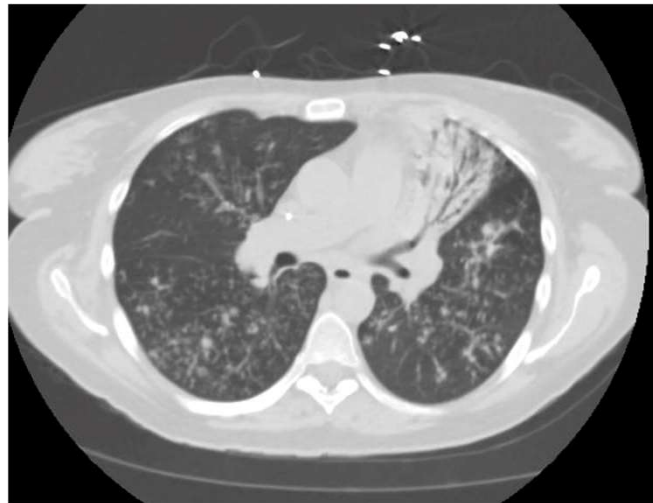


Non Tuberculous Mycobacterium Pulmonary Disease Real Cases

MOHAMED A FAYED, M.D
PULMONARY CRITICAL CARE FACULTY
UCSF FRESNO

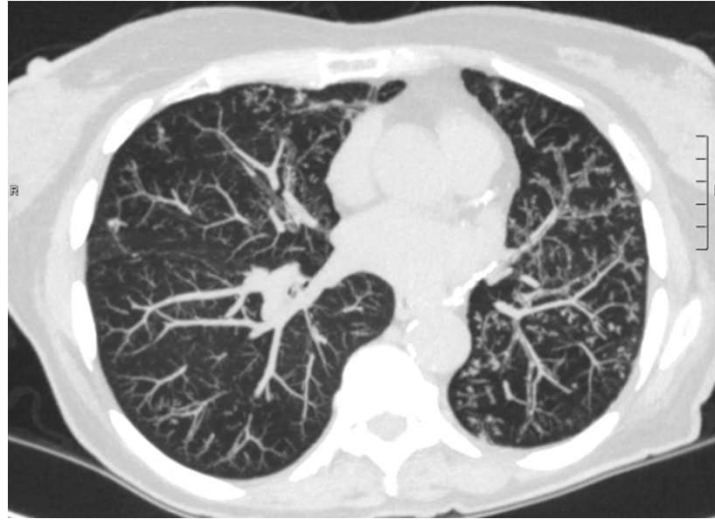
UCSF Fresno Medical
Education Program
School of Medicine

38 y/o F history of CF



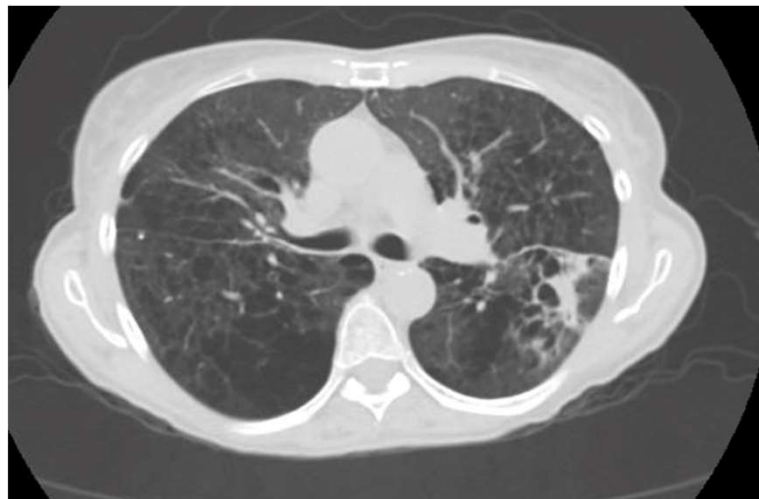
UCSF Fresno Medical
Education Program
School of Medicine

74 y/o F history of COPD



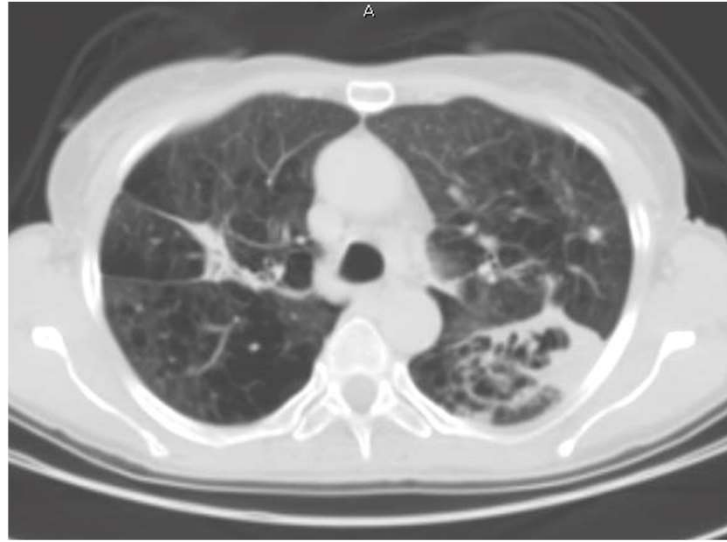UCSF Fresno Medical
Education Program
School of Medicine

59 y/o F Solitary nodule/mass



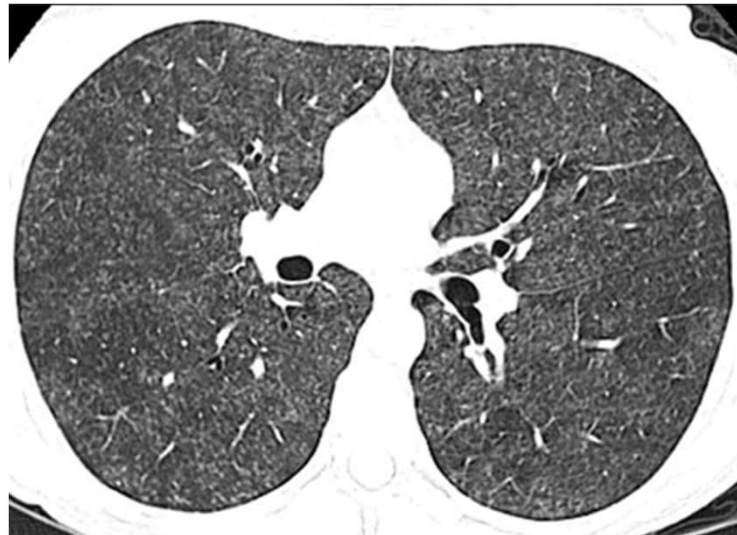UCSF Fresno Medical
Education Program
School of Medicine

59 y/o F with Solitary nodule/mass



UCSF Fresno Medical
Education Program
School of Medicine

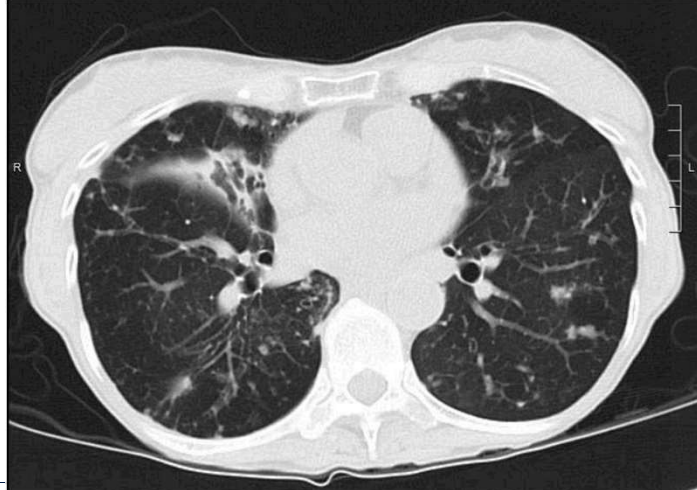
Hypersensitivity pneumonitis
from MAC



UCSF Fresno Medical
Education Program
School of Medicine

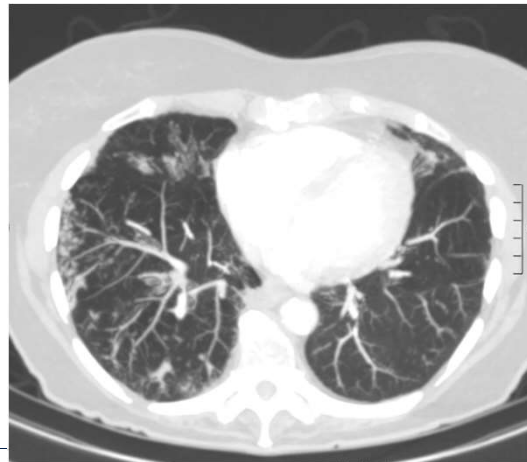
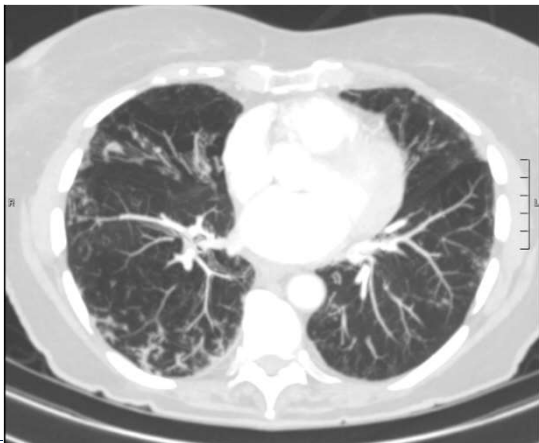
Non pharmacological therapy

- 79 y/o F, had MAC 5 years ago, now with worsening symptoms



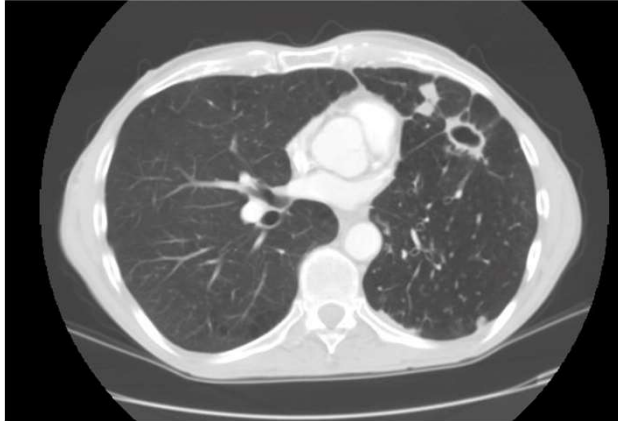
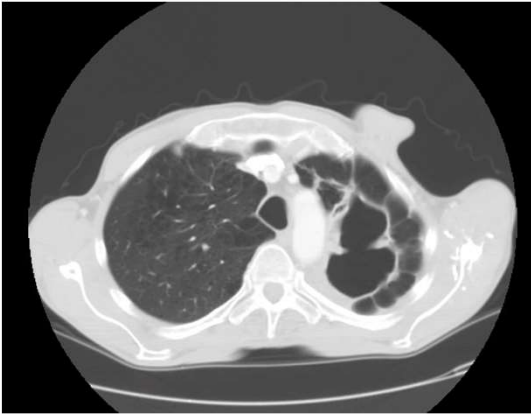
UCSF Fresno Medical
Education Program
School of Medicine

- 97 y/o F with progressive severe cough



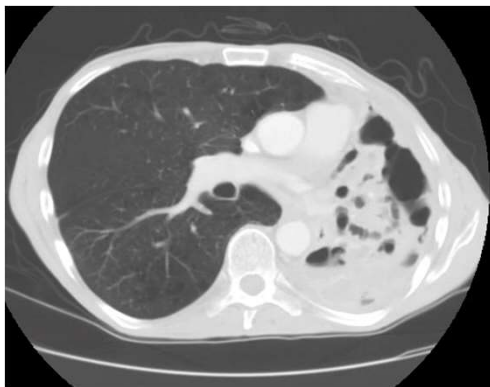
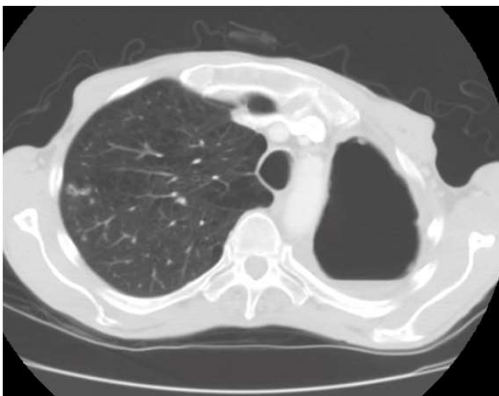
UCSF Fresno Medical
Education Program
School of Medicine

- 62 y/o M with emphysema



UCSF Fresno Medical
Education Program
School of Medicine

- 62 y/o M with emphysema



UCSF Fresno Medical
Education Program
School of Medicine